



ISSN: 2350-0328

**International Journal of Advanced Research in Science,  
Engineering and Technology**

**Vol. 2, Issue 7 , July 2015**

# **Evaluation of changes in splenic lymphoid tissue during visceral leishmaniasis infection in BALB/c mice and after cisplatin in combination with herbal drug treatment**

**Dr. Heena Sachdeva**

Department of Parasitology, Panjab University, Chandigarh, India

**ABSTRACT:** The aim of this study was to observe the morphological changes in spleen during *Leishmania donovani* infection and after cisplatin alone and cisplatin in combination with herbal drug treatment in BALB/c mice. Mice from different groups were sacrificed and spleen samples were obtained after 30 days post infection. The animals were grouped as normal/noninfected, infected, infected and cisplatin treated, infected and cisplatin+*Withania somnifera* treated and infected and cisplatin+*Asparagus racemosus* treated. The results showed expansion in the area of marginal zone, hyperplasia and amyloid deposits. However, cisplatin in combination with herbal drug treatment ameliorated the above mentioned changes.

**KEYWORDS:** Visceral leishmaniasis, *Leishmania donovani*, Spleen, *Asparagus*, *Tinospora*, Cisplatin

## **I. INTRODUCTION**

Leishmaniasis is a disease caused by the protozoan parasites belonging to the genus *Leishmania*. The disease is included in the list of the world's most neglected diseases, prevalent in developing countries [1]. It ranks the second only to malaria, and the control remains a serious problem with ever increasing cases worldwide [2]. *Leishmania* infection continues to have a major impact on public health inducing significant morbidity and mortality mostly in the poorest populations [3].

The control of visceral leishmaniasis (VL) infection till date relies on chemotherapy to alleviate the disease. However, resistance to pentavalent antimonials, which have been the mainstay drugs for the treatment of visceral leishmaniasis, is now common in Indian subcontinent. Latest drug formulations have appreciable efficacy but high cost and therapeutic difficulties limit their use. Moreover, irregular use of drugs in endemic localities intimidates the development of resistance in parasites [4]. Moreover, no licensed vaccine is available till date against any form of leishmaniasis [5]. Therefore, there is a need to identify new and more effective antileishmanial drugs which are cheap and safe as visceral leishmaniasis is a disease of poor. Chemotherapeutic cure of leishmaniasis is mostly dependent upon the development of a protective immune response that would trigger the macrophages to produce toxic nitrogen and oxygen intermediates to eliminate the parasites. Also, it is well documented that immune system synergistically aids to the therapeutic efficacy of antiparasitic drugs [6].

Thus, keeping in mind, the immunosuppression caused during visceral leishmaniasis infection, we have previously used immunomodulatory and protective herbal drugs *T. cordifolia*, *W. somnifera* and *A. racemosus* along with cisplatin against visceral leishmaniasis. Our results showed decrease in parasite load with enhanced generation of DTH responses, increased levels of Th1 cytokines, IgG2a, CD4+ T cells and NK 1.1 cells [7,8,9]. Moreover, histopathological analysis also showed normal architecture of kidney and liver in the mice treated with cisplatin along with herbal drugs. Now, further, we have decided to examine the spleen because it plays a central role in VL. In contrast to other organs like the liver, the spleen maintains the infection during the entire course of VL [10]. During the course of VL, the spleen becomes an evident site of interaction between the immune system and the *Leishmania*, because all of the obligatory participants in the immune response against the parasite are present in large quantities. These include the antigen (live parasites or their debris), antigen-presenting cells, and lymphocytes



capable of responding to these antigens. Changes in the splenic microenvironment have been identified following the experimental infection of mice by a variety of pathogens, including *Leishmania* [11]. Our hypothesis is that such alterations are also present in the course of infection by *L. donovani* in mice and that they reflect a status of susceptibility to the disease. Also, we aimed to observe the effect of the cisplatin alone and cisplatin in combination with herbal drugs (*Asparagus racemosus* and *Tinospora cordifolia*) treatment in infected mice.

## II. MATERIALS AND METHODS

### A. Parasite

*L. donovani* (MHOM/IN/80/Dd8) promastigotes were obtained from the London School of Tropical Hygiene and Medicine, London. The promastigote culture was maintained *in vitro* at  $22\pm 1$  °C in modified Novy, McNeal and Nicolle's (NNN) medium by serial subcultures after every 48-72 h.

### B. Animals

Inbred BALB/c mice were purchased from the Institute of Microbial Technology, Chandigarh, India and those at 6-8 week of age were used for the experiment. All mice were maintained at controlled temperature and humidity, with a 12 h light-dark cycle, and sterile food and water *ad libitum*. Experiments were carried out according to the guidelines of the Committee for the purpose of Control and Supervision of Experiments on Animals (CPCSEA). The ethical clearance for conducting various experiments mentioned in the study on BALB/c mice was taken from Institutional Animal Ethics Committee (IAEC) of the Panjab University, Chandigarh (Approval No. 10/33/CAH/11.02.2010). This work was approved by institutional animal ethics Committee.

### C. *in vivo* infection of mice

The parasites in the logarithmic phase of growth were used for antigen preparation. The culture was pooled and centrifuged for 15 minutes at 2500 rpm. The supernatant was discarded and the pellet (promastigotes) was washed thrice in PBS. Finally, after last wash, supernatant was discarded and to the remaining pellet, 1 ml of PBS was added. The promastigotes were then counted in the Neubauer's chamber. For this promastigote suspension was diluted in 10% buffered formalin. Promastigotes were then adjusted to a concentration of  $10^8$  parasites(promastigotes)/ml. Mice were then injected 0.1 ml of this suspension containing  $10^7$  parasites, intracardially.

### D. Experimental design

For each experimental group, inbred BALB/c mice were used. Nine such groups were selected, A, B, C, D and E. Healthy control Group A) received PBS only, infected control Group B) was infected with  $10^7$  promastigotes of *L. donovani* and kept for 30 days for the progressive development of the disease, Group C) consisted of infected mice treated with cisplatin (Sigma-Aldrich, St. Louis, MO, USA) at the dose of 5mg/kg b.wt./day daily for 5 days, i.p., Groups D and E ) consisted of infected mice treated with cisplatin (5mg/kg b.wt./day daily for 5 days, i.p.) along with herbal drugs (Himalaya Drugs Company, Bangalore, India) *W. somnifera* (350 mg/kg b.wt./day) and *A. racemosus* (650mg/kg b.wt./day) respectively daily for 15 days orally (five days along with cisplatin and then alone for ten days).

### E. Histopathological analysis

Mice from each group were then sacrificed after 30 post infection/post treatment days and spleen was taken out for the histopathological analysis.

## III. RESULTS AND DISCUSSION

Histology of transverse sections of spleen from normal mice showed well defined spleen structure. The red and white pulp was clearly distinguishable. The marginal zone between red and white pulp was also intact (Figure A). However, the transverse sections of spleen of infected mice showed somewhat disorganized marginal zone. Lymphoid hyperplasia was also examined in this study. Hyperplasia was common in animals from the infected and potentially resistant to VL group, and atrophy and lymphoid tissue disorganization were most frequently present in the animals from the infected and potentially susceptible to VL group. Hyperplasia followed by atrophy of the lymphoid follicles may occur in the spleen during the course of VL [12]. However, such atrophy and hyperplasia are not uniform in all compartments of the white pulp. The loss of the architectural structure of splenic tissue has been the subject of recent studies performed in mice infected with *Leishmania* [13] or other pathogens [11]. A variety of changes, including the

loss of cell populations and the impairment of cell migration to the different splenic compartments, have been observed in murine models of visceral leishmaniasis induced by TNF and IL-10 [14]. For instance, studies on experimental models have shown that viral infections may also cause splenic

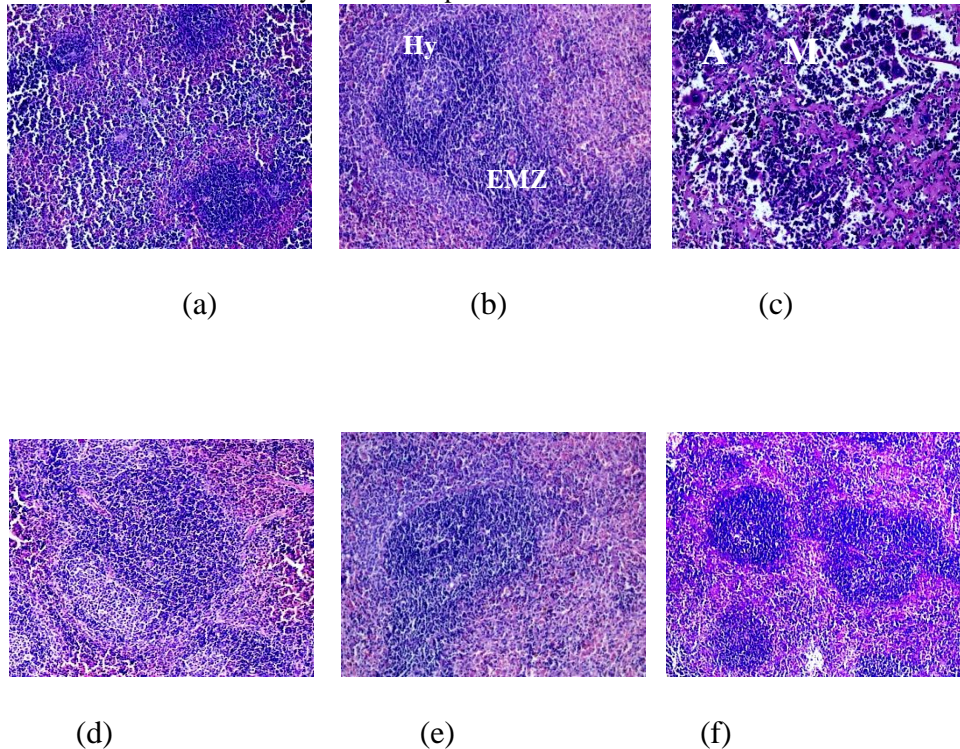


Figure: T.S. of spleen of BALB/c mice stained with haematoxylin and eosin stain (400X). A) Normal control, B) Infected control, C and D) Infected mice treated with cisplatin alone, E) Infected mice treated with cisplatin along with *W. somnifera*, F) Infected mice treated with cisplatin along with *A. racemosus* (Abbreviations: A-Amyloid deposits, EMZ-Expanded marginal zone, Hy-Hyperplasia).

lymphoid tissue disorganization [11]. Nevertheless, the fact that the intensity of white pulp disorganization was higher in animals with splenic parasitism than in those without indicates that an active *Leishmania* infection may play a causal role in a spleen disorganization process. Further studies are necessary to clarify the mechanisms involved in the structural disorganization of the splenic tissue.

Also, in the sections of spleen of infected mice treated with cisplatin white pulp enlargement and expansion of marginal zone was observed. There were numerous areas with amyloid deposition. In addition to this, at some places megakaryocytes were also found (Figure C and D). Our results are also in accordance with the studies of [15] et al. where cisplatin (6mg/kg b.wt.) induced the histological changes in spleen. The volume density of the marginal zone was significantly reduced with increased volume of connective tissue. Similarly, [16] et al. also reported changes in the spleen after cisplatin (5 to 10 mg/kg) treatment which induced karyorrhexis of lymph follicles. However, it was found that in infected mice treated with cisplatin in combination with herbal drugs *W. somnifera* and *A. racemosus* normal spleen structure was observed with no pathological changes in red and white pulp. Marginal zone was intact and there were no amyloid deposits (Figure E and F).

In conclusion, our study shows that visceral leishmaniasis infection is associated with splenic architecture disruption, which is characterized by disorganization of marginal zone and hyperplasia. Moreover, cisplatin treated infected mice also showed histopathological changes. However, cisplatin along with herbal drug treatment showed to ameliorate these changes in infected mice. Therefore, results demonstrated the protective potential of cisplatin in combination with herbal drugs against visceral leishmaniasis infection in BALB/c mice.



ISSN: 2350-0328

# International Journal of Advanced Research in Science, Engineering and Technology

Vol. 2, Issue 7 , July 2015

## REFERENCES

- [1] L.I. McCall, W.W. Zhang and G. Metlashewski, "Determinants for the development of visceral leishmaniasis disease" *PLOS Pathogen* 9(1), pp. e1003053.
- [2] World Health Organization, "The world health report—reducing risks, promoting healthy life" World Health Organization, Geneva, Switzerland, 2012
- [3] A. Badiee, V. S. Heravi, A. Khamesipour and M.R. Jaafari, "Micro/nanoparticle adjuvants for antileishmanial vaccines: present and future trends" *Vaccine*, 31(5), pp. 735-749, 2013.
- [4] N. Singh, M. Kumar and R.K. Singh, "Leishmaniasis: current status of available drugs and new potential drug targets" *Asian Pacific Journal of Tropical Medicine*, 5(6), pp. 486-497, 2012.
- [5] A. Das and N. Ali, "Vaccine development against *Leishmania donovani*" *Frontiers in Immunology*, 3, pp. 99, 2012.
- [6] B.J. Berger and A.H. Fairlamb, "Interaction between immunity and chemotherapy in the treatment of trypanosomiasis and leishmaniasis" *Parasitology*, 105(Suppl.), pp. S71-S78, 1992.
- [7] H. Sachdeva, R. Sehgal and S. Kaur, "Studies on the protective and immunomodulatory efficacy of *Withania somnifera* along with cisplatin against experimental visceral leishmaniasis" *Parasitology Research*, 112(6), pp. 2269-2280, 2013.
- [8] H. Sachdeva, R. Sehgal and S. Kaur, "*Asparagus racemosus* ameliorates cisplatin induced toxicities and augments its antileishmanial activity by immunomodulation *in vivo*" *Parasitology International*, 63(1), pp. 21-30, 2014.
- [9] H. Sachdeva, R. Sehgal and S. Kaur, "*Tinospora cordifolia* as a protective and immunomodulatory agent in combination with cisplatin against murine visceral leishmaniasis" *Experimental Parasitology*, 137, pp. 53-65, 2014.
- [10] J. Carrion, A. Nieto and S. Iborra, *et al.* "Immunohistological features of visceral leishmaniasis in BALB/c mice. *Parasite Immunology*, 28(5), pp. 173-183, 2006.
- [11] C.A. Benedict, C. De Trez, K. Schneider, S. Ha, G. Patterson and C.F. Ware, "Specific remodeling of splenic architecture by cytomegalovirus" *PLOS Pathogen*, 2 (3), pp. e16, 2006.
- [12] C.M. Keenan, L.D. Hendricks, L. Lightner and A.J. Johnson, "Visceral leishmaniasis in the German shepherd dog. II" *Veterinary Pathology* 21 (1), pp. 80-86, 1984.
- [13] C.R. Engwerda, M. Ato, S.E. Cotterell, *et al.* "A role for tumor necrosis factor- $\alpha$  in remodeling the splenic marginal zone during *Leishmania donovani* infection" *American Journal of Pathology* 161 (2), pp. 429-437, 2002.
- [14] M. Ato, S. Stager, C.R. Engwerda and P.M. Kaye, "Defective CCR7 expression on dendritic cells contributes to the development of visceral leishmaniasis" *Nature Immunology* 3 (12), pp. 1185-1191, 2002.
- [15] Z. Milicevic, V. Slepcevic, D. Nikolic, V. Zivanovic and N.M. Milicevic, "Effects of cis-Diamminedichloroplatinum II (Cisplatin) on the splenic tissue of rats: a histoquantitative study" *Experimental and Molecular Pathology* 61(2), pp. 77-81, 1994.
- [16] T. Endo, M. Minami, Y. Monma, H. Saito and M. Takeuchi, "Emesis-related biochemical and histopathological changes induced by cisplatin in the ferret" *The Journal of Toxicological Sciences* 15(4), pp. 235-244, 1990.