



ISSN: 2350-0328

**International Journal of Advanced Research in Science,  
Engineering and Technology**

**Vol. 8, Issue 7 , July 2021**

# **Intraoperative migration of femoral head trial through the iliopsoas muscle during total hip arthroplasty**

**Mohammed s Aljohani\* , Faisal Alrefaei, Seddig Fallatah, Ghada Almohammadi ,Shoog Alfadhel**

Department of Orthopedic Surgery , king Abdelaziz hospital Taif, SAU  
Department of Orthopedic Surgery, King Fahad Hospital, Jeddah, SAU  
Department of Orthopedic Surgery , King Salman armed force hospital, Tabuk, SAU  
Department of Orthopedic Surgery , King Faisal Specialist Hospital, Jeddah, SAU  
Department of Orthopedic Surgery, King Fahad medical city, Riyadh, SAU

**ABSTRACT:** Loss of the femoral head in the soft tissue is one of rare complication of hip arthroplasty. In this report, we present a case of a 62-year-old male with sever hip osteoarthritis his femoral head was lost in the soft tissue surrounding the hip joint and we failed to locate and remove the femoral head successfully we described the interoperative finding ,management and the outcome .

**KEYWORDS:** Total hip arthroplasty , hip surgery, complications of hip surgery ,complex arthroplasty.

## **I. INTRODUCTION**

In total hip arthroplasty, loss of the femoral head trial in the soft tissues is a rare perioperative complication. We reported that the femoral head was lost in the soft tissue surrounding the hip joint and we failed to locate and remove the femoral head successfully. Complications of this kind it's because the femoral head trial is usually made of non-radiolucent material and cannot be detected by conventional X-rays during surgery. The industry should consider the femoral head trial to be manufactured with radiopaque materials.

## **II. CASE PRESENTATION**

A 62-year-old male with severe osteoarthritis was admitted for elective total hip replacement at our institution and he underwent a direct lateral approach (Hardinge approach) with the use of spinal anesthesia, for the total hip replacement we used Zimmer system with a polyethylene size 32 mm , acetabular cup size 52mm and cementless femoral stem size 6mm, and later a 32 mmdiameter femoral head was used. It was mounted and hammered on the femoral neck of the stem. Then, during hip joint relocation to check the stability and range of motion, the femur head trial was lost in the surrounding soft tissue, multiple attempts to find trial head manually were unsuccessful, and all further attempts to find it were not successful.

During the surgery, we used a C-arm x-ray machine to localize it, but there were no signs of the lost femoral head . So, we decide to complete the surgery and close the wound after more than one hour of searching. The postoperative period was normal. The patient started to walk the next day using crutches, with full weight-bearing.

computed tomography (CT) was performed on the first day (Figure 1,2,3) postoperative and showed the femoral head trial just close to the iliac crest bone, in the inner wall of the iliac wing beneath the iliacus muscle. The patient and his family were informed about the complication and the perioperative period was uneventful, then physiotherapy was done as usual in case of primary total hip arthroplasty.

After 1 week from the first surgery, Another operation was performed, with the patient in supine position, an anterior approach was realised, the skin incision was on the iliac crest extended medially and interiorly to the anterior superior iliac spine with care to the lateral cutaneous nerve of the thigh, a Cobb elevator was used to reflect the iliacus muscle medially, and the femoral head was found easily and removed.

This further procedure took 23 min. The post operation plain radiographs showed good positioning of the implants.

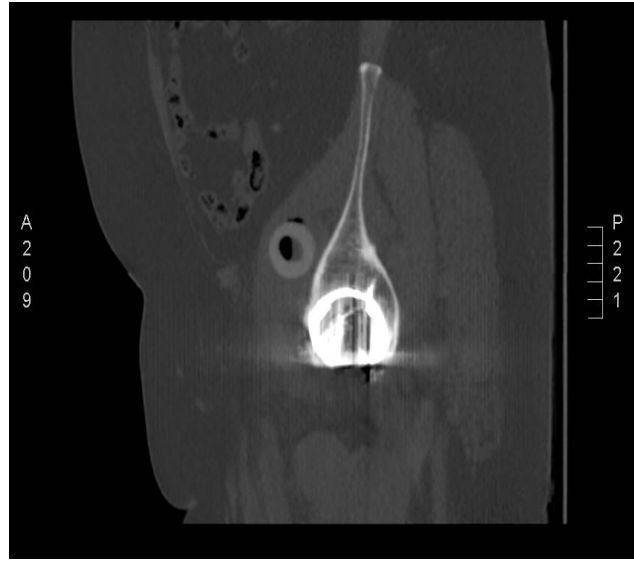
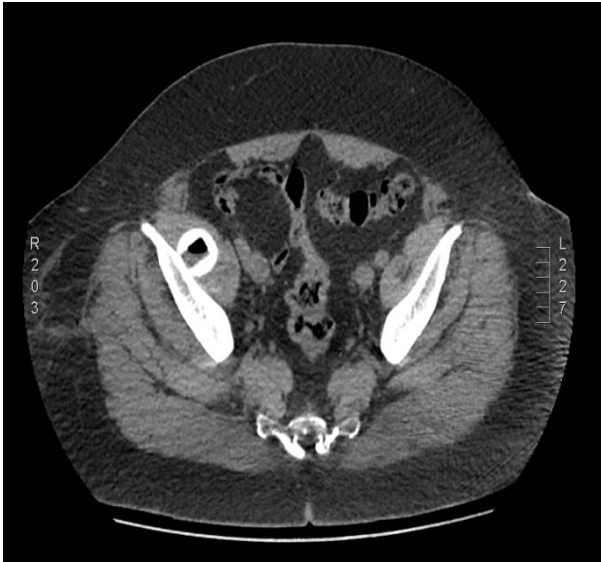


Figure 1. Axial CT scan section shows trial femoral head

Figure 3. Sagittal CT scan section shows trial femoral head

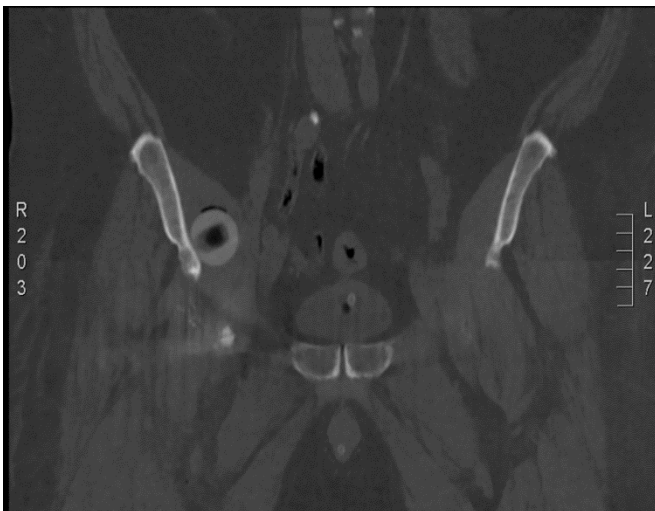

Figure 2. Coronal CT scan section shows trial femoral head

### III. DISCUSSION

In fact, Total hip arthroplasty is one of the most orthopedic surgical procedures used to treat many hip joint diseases. The complications associated with this procedure are known and described in the medical literature. There were only a few cases of dislocation or loss of the femoral head trial had been reported in the literature.



ISSN: 2350-0328

# International Journal of Advanced Research in Science, Engineering and Technology

Vol. 8, Issue 7, July 2021

We believe that the use of computed tomography may be beneficial, although most relevant dislocation reports in the literature state that the trial head is usually located on the inner surface of the pelvis and accessed through a small incision in the iliac crest

We suggested a variety of procedures that will be useful in such cases :

- To check the fit of the trial femoral head on the stem.
- Fill the anterior capsular hole with gauze.
- The manufacturing company should consider a radiopaque femoral head trail to be visible on x-ray.
- Mini computed tomography machine inside the operating room in such case may be helpful.
- If the femoral head trial could not be removed through the wound it is safer to complete the operation and try to retrieve after reposition and making a six to seven-centimeter incision along the iliac crest and extending to the anterior superior iliac spine, reflect the iliopsoas muscle medially in the inner wall of the iliac wing, or in a planned second procedure with a general surgeon.

## REFERENCES

- [1] Liang MH, Cullen KE, Larson MG, et al. Cost-effectiveness of total joint arthroplasty in osteoarthritis. *Arthritis Rheum* 1986;29(8):937.
- [2] Berry DJ, Harmsen WS, Cabanela ME, Morrey BF. Twenty-five-year survivorship of two thousand consecutive primary Charnley total hip replacements: factors affecting survivorship of acetabular and femoral components. *J Bone Joint Surg Am* 2002;84:171.
- [3] Soderman P, Malchau H, Herberts P. Outcome after total hip arthroplasty: part I. General health evaluation in relation to definition of failure in the Swedish National Total Hip Arthroplasty Register. *Acta Orthop Scand* 2000;71:354.
- [4] Bozic KJ, Kurtz SM, Lau E, et al. The epidemiology of revision total hip arthroplasty in the United States. *J Bone Joint Surg Am* 2009;91(1):128.
- [5] Madsen WY, Mitchell BS, Kates SL. Successful intraoperative retrieval of dislocated femoral trial head during total hip arthroplasty. *J Arthroplasty* 2012;27(5):820.e9
- [6] Khanuja HS, Vakil JJ, Goddard MS, Mont MA. Cementless femoral fixation in total hip arthroplasty. *J Bone Joint Surg Am* 2011;93(5):500.
- [7] Sculco TP, Jordan LC, Walter WL. Minimally invasive total hip arthroplasty: the Hospital for Special Surgery experience. *Orthop Clin North Am* 2004;35(2):137.
- [8] Wall SJ, Mears SC. Analysis of published evidence on minimally invasive total hip arthroplasty. *J Arthroplasty* 2008;23(7 Suppl):55.
- [9] Lewinnek GE, Lewis J. Dislocations after total hip-replacement arthroplasties. *J Bone Joint Surg Am* 1978;60:217
- [10] Alfonso D, Idjadi J, Lamont JG. Retrieval of a trial femoral head that displaces into the periacetabular soft tissue during mini-incision total hip arthroplasty. A case report. *J Bone Joint Surg Am* 2006;88:866.
- [11] Batouk O, Gilbert M, Jain R. Intraoperative dislocation of the trial femoral head into the pelvis during total hip arthroplasty: a case report. *J Bone Joint Surg Am* 2001;83.
- [12] Bicanic G, Crnogaca K, Simunovic M, Delimar D. Dislocated trial femoral head during total hip arthroplasty: review of the literature and the new algorithm for treatment. *BMJ Case Rep* 2015;20153-A(10):1549.
- [13] Hamoui M, Larbi A, Delannis Y, et al. Pitfall in total hip arthroplasty: intraoperative migration of the trial femoral head through the iliopsoas muscle. *Eur J Orthop Surg Traumatol* 2012;22(8):713.
- [14] Vertelis A, Vertelis L, Tarasevicius S. Trial femoral head loss into the soft tissues of pelvis during primary total hip replacement: a case report. *Cases J* 2008;1(1):151.
- [15] Kalra K, Ries MD, Bozic KJ. Intrapelvic displacement of a trial femoral head during total hip arthroplasty and a method to retrieve it. *J Arthroplasty* 2011;26(2):338.e21.